

# A Prospective Study for Effect of Wound or Scar Tissue Massage after Thyroidectomy on Neck Discomfort and Voice Change

Hemin Qabel Hasan<sup>1\*</sup>, Ali Al Dabbagh<sup>2</sup>

<sup>1</sup>General Directorate of Health, Erbil, Iraq.

<sup>2</sup>College of Medicine, Hawler Medical University, Erbil, Iraq.

\*Correspondence to: Hemin Qabel Hasan (E-mail: heminqabel@gmail.com)

(Submitted: 03 September 2021 – Revised version received: 28 September 2021 – Accepted: 16 October 2021 – Published online: 26 December 2021)

## Abstract

**Objectives:** This study aimed to found and selecting the causes behind neck discomfort and change in the voice following thyroidectomy and to determine the efficacy of wound massaging technique on decreasing and relief such symptoms.

**Methods:** Totally 55 patients all females who underwent thyroidectomy were included in our study, the patients were divided in to two groups (26 in the experimental group and 29 in the control group). The massaging technique was instructed to all patients in the experimental group 1 week postoperatively and the feedback were received from patients after 2 weeks and 4 weeks from instruction time. The analysis was achieved for both groups of patients.

**Results:** After exclusion of laryngeal pathologies post operatively. The recovery rate of the patients in the experimental group from post operation adhesions was obviously and significantly much more better recovery from subjective voice impairment score (SVIS) and neck discomfort score (NDS) which was represented by swallowing impairment score (SIS). (all  $P < .01$ ) in compare with the patients in control group. Those results indicates that localized adhesions following total thyroidectomy operation could be included in affection of general movement as well as vertical movements of the larynx and the wound massaging technique might help patients recovering the normal general movement of the larynx postoperatively.

**Conclusion:** Discomfort of the neck, pulling neck sensation, and voice or phonation changes after total thyroidectomy surgery might due to local surgical adhesions of the wound which possibly accompanied with impairment of vertical movement of larynx. so, releasing of such adhesions could help the patients to recover much more quickly from mentioned undesirable symptoms postoperatively and start their normal daily activities.

**Keywords:** Total thyroidectomy operation, neck massage technique, voice change, phonation, scar

## Introduction

Change of the voice and discomfort of the neck are two undesirable outcomes after total thyroidectomy operation. There are patients that feel adhesive symptoms such as impairment or improper swallowing and pulling sensations when the neck extended.<sup>1</sup> Those unpleasant subjective neck symptoms could be caused by adhesive bands between the larynx and strap muscles as well as surrounding subcutaneous tissues which restrict the vertical movement of the larynx during speaking or swallowing. Such difficulties and limitations of the larynx movement will make the patients suffering from localized discomfort.<sup>2</sup>

A group of patients also complaining from change of the voice after total thyroidectomy operation. This might be due to trauma to the laryngeal nerves, intrinsic muscles and structures, or distruction of extra laryngeal muscles.<sup>3</sup> Injury of recurrent laryngeal nerve is reported as the main cause of changing voice, followed by injury to the superior laryngeal nerve (SLN) or cricothyroid muscle.<sup>4,5</sup> However, keeping the nerve intact is not the only point to have a normal voice and phonation postoperatively.<sup>6</sup> Limited larynx mobilization can alters normal movements of laryngeal muscles, those changes will make these patients feeling that their phonation is different and changed.<sup>2</sup> Trials have been attempted by some surgeons to remove such adhesions using specific measures.<sup>7-10</sup>

However, these trials resulted in a more surgical adhesions, and their outcomes are usually under expectations. Thus, nonsurgical adhesion release procedures i.e. (massaging) are mandatory. Wound massage can detach the fibrous

tensions of surgery adhesions, releasing shortened bands and adhesions in the muscles and underlying subcutaneous structures, will elevate the range of motion as well as returning back to the normal action this in turn make the patients free of complains.<sup>11,12</sup> However, the exact effect of this technique as an approach to relief discomforts of the neck and phonation changes after total thyroidectomy operation is not clear-cut. For this reason, the aim of this research was to clarify the causes of neck discomfort and phonation change as well as testing our technique on relieving of those complains. Outcomes of this research might improve our perception of neck discomfort and phonation change after total thyroidectomy operation.

## Patients and Methods

A total of 57 patients with different thyroid pathologies who underwent total thyroidectomy from December 2018 to December 2019 were included in this prospective study. Patients were selected from one public and two private hospitals in Erbil governorate. Selection was determined by choosing of a random number of patients.

Wound massaging technique were illustrated to the participants in the experimental group. One week after total thyroidectomy operation, the experimental group started wound massage technique (minimum 10 minutes, achieved 3 times a day). Patient information is clarified in [Figure 2](#).

**Inclusion criteria** were (1) indicated cause for thyroidectomy and (2) history of total thyroidectomy operation.

**Exclusion criteria** were (1) abscess or hematoma formation (2) wound infection; and (3) patients with a recurrent thyroid pathology preoperatively; (4) history of previous neck surgery.

Before the operation, the larynx was examined with indirect laryngoscopy. Patients with abnormal vocal fold movement were also excluded.

Finally, 55 patients all women were included. After total thyroidectomy operation, patients had received regular follow up and clinical examination. The initial outcome was the relationship between neck discomfort/change in phonation and wound adhesion. The secondary outcome based on patient's objective and subjective parameters after achieving wound massage technique.

## Surgical Methods

All Patients who had undergone classic total thyroidectomy operation were included in this research. Total thyroidectomy was defined as total bilateral thyroidectomy. Sternohyoid and sternothyroid muscles were dissected and retracted laterally during surgery without cutting them. There was no evidence of recurrent laryngeal nerve injury which was confirmed by laryngoscope postoperatively. The superior thyroid vessels were ligated close to the thyroid capsule to avoid superior laryngeal nerve injury.

### Subjective Clinical Assessments

Change in the voice and phonation as well as neck discomfort were checked by depending on subjective voice impairment score (SVIS) and neck discomfort score (NDS) or swallowing impairment score (SIS).

### Wound Massage

Experimental group of patients all instructed to perform wound massaging technique, (should be performed at least 10 minutes, 3 times a day) after one week from total thyroidectomy operation, to make sure that the wound is healed and there were no signs of infection.

The massage technique was aimed to detach the tension bands between the strap muscles and the larynx in order to facilitate the vertical movement of the larynx which in turn improves the unpleasant neck pulling sensation felt by the patient.

The control group of patients were not informed about the wound massage. They received reminders via phone calls and were asked to visit the clinic on the 7th postoperative day and re-evaluated for their subjective symptoms (neck discomfort and voice change) after two weeks and four weeks from first visit i.e. (a week after the operation).

### The Massage Technique of the Wound was Instructed as the Following

1. Softly make a pressure on the site of the operation (healed wound) and moving it over the underlying tissues with your fingers.
2. Perform big circles by moving the skin over the underlying tissues rather than rubbing on the skin surface.
3. Make a vertical movement on the incision site with your fingers extend it toward the chin.
4. Continue massaging for about 10 minutes at a time, at least 3 times a day.

5. Do not perform the massage, and notify your doctor once you feel: pain, redness and discharge.

## Results

### Patient Characteristics

Initially 57 female patients who had undergone total thyroidectomy operation were included, and finally total number of patients become 55 after exclusion of two patients one from experimental group because of skin infection and other from control group because of lost follow up, from those (55) patients (26 patients in the experimental and 29 patients in the control group). Their clinical characteristics are summarized in Table 1.

### The Compliance Rates by Time in the Experimental Group of Patients

The wound massage compliance percentage was 88.5% for average massages per day and 80.4% for the length of massaging (Table 2).

### Subjective Data Analysis

Subjective voice impairment score (SVIS), subjective neck discomfort score (NDS) and swallowing impairment score (SIS) was followed (one week postoperatively before massaging) and two weeks massaging period with four weeks massaging period after first week postoperatively.

At 7 days postoperatively before massaging, SVI score was  $(95 \pm 4)\%$  for the control group and  $(96 \pm 3)\%$  for the experimental group. At 2 weeks massaging period postoperatively, SVI score was  $(84 \pm 5)\%$  in the control group and  $(13 \pm 2)\%$  in the experimental group. At 4 weeks massaging period postoperatively, SVI scores was  $60\% \pm 3\%$  for control group and  $3\% \pm 1\%$  for experimental group and significantly different between the 2 groups was ( $P = 0.001$ ) (Tables 3 and 4), (Figures 1 and 2).

Wound massaging technique also decreased the subjective neck discomfort score (NDS), as well as SIS (subjective swallowing impairment score) which was performed for 2 weeks and 4 weeks total massaging period postoperatively. At 1st week postoperatively before massaging, SIS and NDS for control and experimental groups were  $(96 \pm 6)\%$  and  $(97 \pm 4)\%$ ,

Table 1. Clinical characteristics of patients underwent total thyroidectomy

Age: Range (28–53) years	Median = 40.5
Sex: All are females	
Hospital stays: All 1 day	
Histopathology outcomes: Multi pathologies	
Drain: Off on discharge day	

Table 2. Compliance rates by period in the experimental group

Description	Target goal	Accomplished	Compliance
Average number of massages per day	Three	2.5 times	88.5%
Average min per massage	10 min	8.03 min	80.4%

Table 3. Subjective analysis of voice impairment, neck discomfort and swallowing impairment scores (SVIS, NDS, SIS) for experimental patient group

Subjective symptoms	Postoperative 1 week before massage	Postoperative 2 weeks massaging	Postoperative 4 weeks massaging	P
VIS	(96 ± 3)%	(13 ± 2)%	(3 ± 1)%	< 0.001
NDS or SIS	(97 ± 2)%	(10 ± 2)%	(3 ± 1)%	< 0.001

VIS, voice impairment score; NDS, neck discomfort score; SIS, swallowing impairment score.

Table 4. Subjective analysis of voice impairment, neck discomfort and swallowing impairment scores (SVIS, NDS, SIS) for control patient group

Subjective symptoms	Postoperative 1 week	Postoperative 2 weeks	Postoperative 4 weeks	P
VIS	(95 ± 4)%	(84 ± 5)%	(60 ± 3)%	0.541
NDS or SIS	(96 ± 6)%	(81 ± 4)%	(62 ± 5)%	0.573

VIS, voice impairment score; NDS, neck discomfort score; SIS, swallowing impairment score.

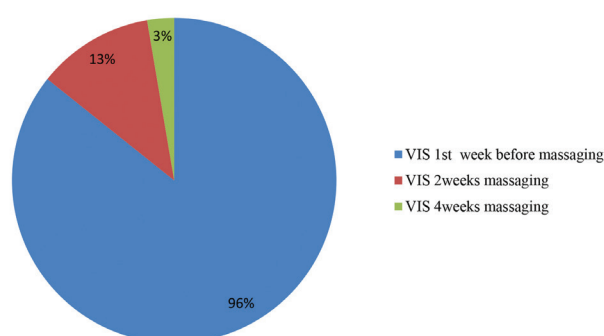


Fig. 1 Distribution of experimental group VIS (subjective voice impairment score) pre and post massaging periods.

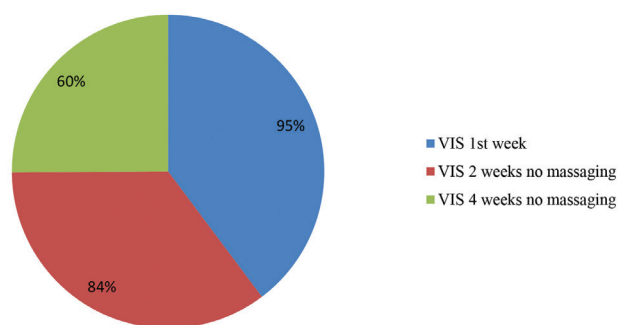


Fig. 2 Distribution of control group VIS (subjective voice impairment score) all times without massaging.

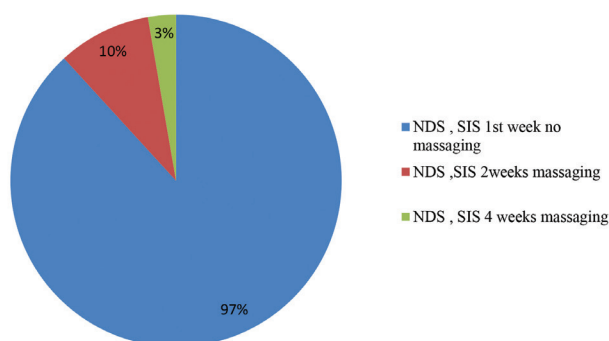


Fig. 3 Distribution of experimental group NDS (neck discomfort score), SIS (swallowing impairment score) pre and post massaging periods.

respectively. At 2 weeks massaging period postoperatively, SIS and NDS for control and experimental groups were (81 ± 4)% and (10 ± 2)%, respectively. At 4 weeks massaging period postoperatively SIS and NDS for control and experimental groups were (62 ± 5)% and (3 ± 1)%, respectively. This represented a significant difference in SIS and NDS between the 2 groups ( $P = 0.001$ ) (Table 3 and 4), (Figures 3, 4 and 5) and indicated that wound massaging technique can decrease subjective swallowing discomfort and neck discomfort.

## Discussion

Thyroid operations (total thyroidectomy) now a day is becoming more abandoned due to rising in the diagnosis of

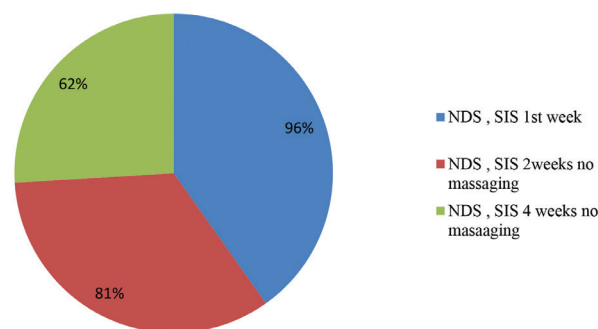


Fig. 4 Distribution of control group NDS (neck discomfort score), SIS (swallowing impairment score) all times without massaging.

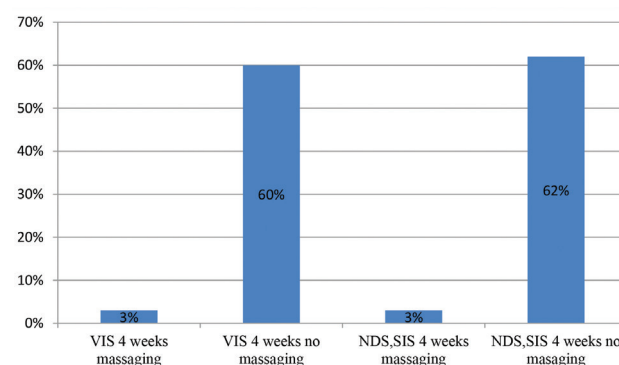


Fig. 5 Final percentages after 4 weeks with and without massaging technique.

thyroid pathologies and majority of the patients with thyroid operations have excellent pathologic outcomes.<sup>13-15</sup> However, a lot of patients with no obvious stigmata of nerve injury still complaining from neck pulling sensation and phonation change.<sup>16-19</sup> This phenomenon has been known as a (functional post-thyroidectomy syndrome).<sup>20,16,21-24</sup>

These post-thyroidectomy neck unpleasant felling and phonation change often tend to disappear gradually, although they can affect individual's life quality postoperatively.<sup>25</sup>

The reasons and the management of those unpleasant neck felling and voice alteration have not been analyzed thoroughly. Therefore, characterizing these symptoms are crucial for alleviating patient's felling and rehabilitation of voice.

In the post total thyroidectomy period, the larynx is often adheres to its overlying strap muscles and subcutaneous tissue, the procedure of total thyroidectomy require lateral traction and/or cutting of strap muscles (sternohyoid and sternothyroid). This maneuver might damage the strap muscles which interfere with the normal contour of the surrounding tissues, this in turn leads to contracture of the wound and adhesion formation between the larynx and its surrounding, which diminish it's vertical movement that make the patient experience the neck pulling sensation and phonation change during speech.<sup>26-28</sup>

The technique and procedure of wound massaging probably lead to decrease those adhesions by elevating the circulation to that area, thus leading to destruction of the adhesion, this in turn can aid in the process of healing postoperatively.

Some researchers have revealed that massage technique will increase the soft tissue extensibility.<sup>29-31</sup>

Thus, we suspect that massaging technique can help patients improve the voice change and neck discomfort.

If there is no wound pain at the day tenth postoperatively, wound massage can be started by gently moving the scar vertically up and down and in clockwise and counterclockwise directions.

Massaging should be only initiated when the wound is completely healed (when there are no open areas, redness and pain). In my research I have realized that wound massage can increase the range of motion of the larynx. Our results explained that total thyroidectomy operation most probably will lead to wound adhesions and those wound adhesion could be dealt with or released by the technique of wound or scar tissue massaging, as well as decreasing the felling of pulling neck sensation, discomfort of the neck and phonation voice change.

In some situations, after total thyroidectomy the adhesions can be so strong and severe. It may not become better or reduce spontaneously during periods of time. In such a condition, discomfort of the neck with change in phonation may not reduced for that long period of time. The skin of incision site may be also looks to be adherent to the underlying tissues and trachea. Especially when the patient start swallowing of (saliva, any liquids, or different kind of food), the operation site skin moving up and down in one portion. In such conditions, massaging technique overlying the stuck-skin location is beneficial.

The Neck massaging technique can be a tool and a cause for releasing of those adhesions, giving the larynx a space for its movement much more smoothly. That technique could also improve the phonation by elevating the voice pitch and resolving neck pulling sensation.

The phonation change after total thyroidectomy operation has been historically believed to be as the outcome of iatrogenic injury to the laryngeal nerves at the time of thyroidectomy operation.<sup>28,32</sup> Operation trauma to the recurrent laryngeal nerve is an unwanted concerning morbidity outcome of thyroid gland operation. As well as, changing in the voice it is also has been documented in a number of cases when there was an intact laryngeal nerve. In these conditions, the phonation changes have been included to be caused by surgical injury, intubation of trachea, arytenoids injury, or laryngeal adhesion with strap muscles or overlying subcutaneous tissues.<sup>2,19,33</sup>

In this research, voice evaluation and alteration which caused by limited vertical movement of the larynx following total thyroidectomy operation.

Subjective voice impairment score (SVIS) is referred to the (sound pitch variation) during speaking and phonation. In the present research, (SVIS) was decreased following total thyroidectomy operation. However, the sounding and phonation is increased obviously and clearly after technique of wound massaging. So, this finding is indicating the changes and alterations which was caused by neck strap muscle adhesions. The Strap muscles have also external laryngeal frame actions for process of phonation. In Some researches have been documented that strap muscles in the neck are associated with frequency and they will play regulator role for sound pitch control by changing the relationship between the cricoid and thyroid cartilages.<sup>26,34,35</sup> In reality, it has been documented that electrically the strap muscles have been pronounced their activities at low pitches, and those decreased activities will results in sound pitch elevation.<sup>26,36</sup> Thus strap muscle adhesion bands can changes the function of larynx to raise the sound pitch.<sup>35</sup>

NDS (Neck discomfort scoring) or pulling neck sensation which was caused by limited vertical movement of larynx also had nearby the similar results.

This study will support the fact that phonation and voice changes as well as neck discomfort are could be associated with total thyroidectomy operation by the mechanism of wound adhesion. Therefore, releasing of those adhesions likely could plays an important role in vertical movement flexibility of the larynx and giving us the short recovery interval postoperatively for voice and phonation change with neck discomfort.

The phonation change after total thyroidectomy could be also have a relation to SLN injury. The best way to detect the trauma to the SLN is by electromyography (EMG). However, the patients are generally felling unpleasant to participate in this invasive investigation. Therefore, we decided to find out the SLN palsy by depending on acoustic data because it has been documented those reductions in HPS (high pitch sound) is generally could be due to SLN injury.<sup>2,37</sup> With SLN damage HPS is usually decreased and diplophonia is occurred. In this research HPS was not significantly and obviously altered.

In this study two main symptoms which are voice change and neck discomfort both of them after wound massaging technique were significantly lower at 2 weeks than at 4 weeks of massaging period postoperatively. In other hand, the thyroidectomy-induced adhesions were also responsible for discomfort of neck and alterations in voice performances. Those outcome results are recorded with previous researches.<sup>2,19-21,38-40</sup>

To the best of what we are knowing, usage of wound massaging technique to deal with neck discomfort, phonation and voice change followed total thyroidectomy operation has not been officially reported yet. And there are some limitations

in this research, our outcomes and results will provide a very beneficial data information about clinical neck discomfort and phonation change treatment. Further researches with a larger sample sizes and more period of follow-up frequencies are required to find out differences in-between different age and gender group of patients.

Researches on different antiadhesive agents that have ability to decrease neck discomfort and voice change after total thyroidectomy operation are especially mandatory in the near future. Although the method of adhesion analysis had been used in this research was subjective, but a great deal of evidence presents which suggesting that wound massaging technique is very helpful to shorten the recovery time after total thyroidectomy surgery. In addition, we can't find a validated analysis way for measuring neck adhesion grossly after total thyroidectomy operation. That's why we will need to validate this analysis method further more in the near future. In this research all patients had intact neural function postoperatively. And however, we don't use the EMG for SLN injury. When there is a trauma to SLN, the subjective voice change symptoms are near to those seen with larynx movement restrictions. And a gross SLN injury may not always be diagnosed.

This may a little bit causing some sort of confusion. However, this research is focusing on neck discomfort and voice change as general.

Therefore, we focused on HPS (high pitch sound) as a differentiation tool for SLN injury. For further voice evaluation, EMG is required to rollout the damage of SLN.

## Conclusion and Recommendation

Neck discomfort and voice change after thyroidectomy are mostly related to local scar adhesion, possibly associated with impairment of laryngeal vertical movement. Scar tissue release could help patients recover from neck discomfort and voice changes after thyroidectomy by restoring the general movement of the larynx.

We recommend to start neck massaging for at least two weeks after stitch removal and to be as much as possible less aggressive during thyroid operation.

## Conflicts of Interest

None to declare. ■

## References

- Park WS, Chung YS, Lee KE, Kim HY, Choe JH, Koh SH, et al. Anti-adhesive effect and safety of sodium hyaluronate and sodium carboxymethyl cellulose solution in thyroid surgery. *Asian J Surg*. 2010; 33:25–30.
- Hong KH, Kim YK. Phonatory characteristics of patients undergoing thyroidectomy without laryngeal nerve injury. *Otolaryngol Head Neck Surg*. 1997; 117:399–404.
- Sataloff RT, Spiegel JR, Carroll LM, Heuer RJ. Male soprano voice: a rare complication of thyroidectomy. *Laryngoscope*. 1992; 102:90–93.
- Holt GR, McMurray GT, Joseph DJ. Recurrent laryngeal nerve injury following thyroid operations. *Surg Gynecol Obstet*. 1977; 144:567–570.
- Hunt CJ. The superior and inferior laryngeal nerve as related to thyroid surgery. *Am Surg*. 1961; 27:548–552.
- Painter NS. The results of surgery in the treatment of toxic goitre. A review of 172 cases. *Br J Surg*. 1960; 48:291–296.
- Woo SH. Endoscope-assisted transoral thyroidectomy using a frenotomy incision. *J Laparoendosc Adv Surg Tech A*. 2014; 24:345–349.
- Woo SH. Endoscope-assisted intraoral removal of the thyroid isthmus mass using a frenotomy incision. *J Laparoendosc Adv Surg Tech A*. 2013; 23:787–790.
- Woo SH, Jeong HS, Kim JP, Park JJ, Baek CH. Endoscope-assisted intraoral removal of ectopic thyroid tissue using a frenotomy incision. *Thyroid*. 2013; 23:605–608.
- Kim JP, Park JJ, Woo SH. No-Scar Transoral Thyroglossal Duct Cyst Excision in Children. *Thyroid*. 2018; 28:755–761.
- Boyles R, Toy P, Mellon Jr J, Hayes M, Hammer B. Effectiveness of manual physical therapy in the treatment of cervical radiculopathy: a systematic review. *J Man Manip Ther*. 2011; 19:135–142.
- Senbursa G, Baltaci G, Atay A. Comparison of conservative treatment with and without manual physical therapy for patients with shoulder impingement syndrome: a prospective, randomized clinical trial. *Knee Surg Sports Traumatol Arthrosc*. 2007; 15:915–921.
- Kim K, Gu MO, Jung JH, Hahm JR, Kim SK, Kim JH, Woo SH. Efficacy of a Home-Based Exercise Program After Thyroidectomy for Thyroid Cancer Patients. *Thyroid*. 2018; 28:236–245.
- Kim KH, Woo SH. An Occupational Study in Nurses: Prevalence of Thyroid Nodules and Cancer in Comparison to Health Check-up Female. *Clin Exp Otorhinolaryngol*. 2016; 9:252–256.
- Won SJ, Kim RB, Kim JP, Park JJ, Kwon MS, Woo SH. The prevalence and factors associate with vocal nodules in general population: Cross-sectional epidemiological study. *Medicine (Baltimore)*. 2016;95: e4971.
- Pereira JA, Girvent M, Sancho JJ, Parada C, Sitges-Serra A. Prevalence of long-term upper aerodigestive symptoms after uncomplicated bilateral thyroidectomy. *Surgery*. 2003; 133:318–322.
- Rosato L, Carlevato MT, De Toma G, Avenia N. Recurrent laryngeal nerve damage and phonetic modifications after total thyroidectomy: surgical malpractice only or predictable sequence? *World J Surg* 2005; 29:780–4.
- Sinagra DL, Montesinos MR, Tacchi VA, Moreno JC, Falco JE, Mezzadri NA, et al. Voice changes after thyroidectomy without recurrent laryngeal nerve injury. *J Am Coll Surg*. 2004; 199:556–560.
- Stojadinovic A, Shaha AR, Orlikoff RF, Nissam A, Kornak MF, Singh B, et al. Prospective functional voice assessment in patients undergoing thyroid surgery. *Ann Surg*. 2002; 236:823–832.
- Lombardi CP, Raffaelli M, D'Alatri L, Marchese MR, Rigante M, Paludetti G, et al. Voice and swallowing changes after thyroidectomy in patients without inferior laryngeal nerve injuries. *Surgery*. 2006; 140: 1026–1032 discussion 32–4.
- Lombardi CP, Raffaelli M, D'Alatri L, De Crea C, Marchese MR, Maccora D, et al. Video-assisted thyroidectomy significantly reduces the risk of early post-thyroidectomy voice and swallowing symptoms. *World J Surg*. 2008; 32:693–700.
- Stojadinovic A, Henry LR, Howard RS, Gurevich-Uvena J, Makashay MJ, Coppit GL, et al. Prospective trial of voice outcomes after thyroidectomy: evaluation of patient-reported and clinician-determined voice assessments in identifying postthyroidectomy dysphonia. *Surgery*. 2008; 143:732–742.
- Henry LR, Solomon NP, Howard R, Gurevich-Uvena J, Horst LB, Coppit G, et al. The functional impact on voice of sternothyroid muscle division during thyroidectomy. *Ann Surg Oncol*. 2008; 15:2027–2033.
- Akyildiz S, Ogut F, Akyildiz M, Engin EZ. A multivariate analysis of objective voice changes after thyroidectomy without laryngeal nerve injury. *Arch Otolaryngol Head Neck Surg*. 2008; 134:596–602.
- Lombardi CP, Raffaelli M, De Crea C, D'Alatri L, Maccora D, Marchese MR, et al. Long-term outcome of functional post-thyroidectomy voice and swallowing symptoms. *Surgery*. 2009; 146:1174–1181.
- Sonninen A, Hurme P, Laukkanen AM. The external frame function in the control of pitch, register, and singing mode: radiographic observations of a female singer. *J Voice*. 1999; 13:319–340.
- Williams RG, Lesser TH, Foster M, Griffith G. Altered laryngeal function following thyroidectomy. *Clin Otolaryngol Allied Sci*. 1989; 14:281–283.
- Hong KH, Yang WS, Park MJ, Oh JS, Han BH. Changes in Oral Vowel Sounds and Hyoid Bone Movement After Thyroidectomy. *Clin Exp Otorhinolaryngol*. 2017; 10:168–173.
- Ault P, Plaza A, Paratz J. Scar massage for hypertrophic burns scarring: a systematic review. *Burns*. 2018; 44:24–38.
- Min ZH, Zhou Y, Jing L, Zhang HM, Wang S, Chen WH, et al. [Case-control study on Chinese medicine fumigation and massage therapy for the

- treatment of knee stability and functional recovery after anterior cruciate ligament reconstruction operation]. *Zhongguo Gu Shang*. 2016; 29:397–403.
31. Moyer CA. Affective massage therapy. *Int J Ther Massage Bodywork*. 2008; 1:3–5.
  32. Hong KH, Ye M, Kim YM, Kevorkian KF, Berke GS. The role of strap muscles in phonation—in vivo canine laryngeal model. *J Voice*. 1997; 11:23–32.
  33. Kark AE, Kissin MW, Auerbach R, Meikle M. Voice changes after thyroidectomy: role of the external laryngeal nerve. *Br Med J (Clin Res Ed)*. 1984; 289:1412–1415.
  34. Hong KH, Kim HK, Kim YH. The role of the pars recta and pars oblique of cricothyroid muscle in speech production. *J Voice*. 2001; 15:512–518.
  35. Niimi S HS, Kobayashi N. Raising role of the sternothyroid muscle—an electromyographic study of two tenors. 1991.
  36. Hirano M, Koike Y, von Leden H. The sternohyoid muscle during phonation. Electromyographic studies. *Acta Otolaryngol*. 1967; 64:500–507.
  37. Robinson JL, Mandel S, Sataloff RT. Objective voice measures in non-singing patients with unilateral superior laryngeal nerve paresis. *J Voice*. 2005; 19:665–667.
  38. de Pedro Netto I, Fae A, Vartanian JG, Barros AP, Correia LM, Toledo RN, et al. Voice and vocal self-assessment after thyroidectomy. *Head Neck*. 2006; 28:1106–1114.
  39. Musholt TJ, Musholt PB, Garm J, Napiontek U, Keilmann A. Changes of the speaking and singing voice after thyroid or parathyroid surgery. *Surgery*. 2006; 140:978–988 discussion 88–9.
  40. Soyulu L, Ozbas S, Uslu HY, Kocak S. The evaluation of the causes of subjective voice disturbances after thyroid surgery. *Am J Surg*. 2007; 194:317–322.

This work is licensed under a Creative Commons Attribution-NonCommercial 3.0 Unported License which allows users to read, copy, distribute and make derivative works for non-commercial purposes from the material, as long as the author of the original work is cited properly.