

# Optimization of Colon Tissue Protection in Strangulated Hernias: The Role of Hypothermia

Hamdamov Odil Komilovich<sup>1</sup>, Mardonov Jamshid Normurotovich<sup>\*1,2</sup>, Sadykov Rustam Abrarovich<sup>2</sup>, Ochilov Jahongir Ulugbek ugli<sup>1,2</sup>, Khudayberganova Nasiba Shakirovna<sup>1,2</sup>, Amanov Bakhrom Bakhadirovich<sup>1,2</sup>, Mirzaev Khondamir Alisher ugli<sup>1,2</sup>

<sup>1</sup>Tashkent State Dental Institute, Tashkent, Republic of Uzbekistan.

<sup>2</sup>State Institution "Republican Specialized Scientific – Practical Medical Center of Surgery Named After Academician V.Vakhidov", Tashkent, Republic of Uzbekistan.

<sup>3</sup>The Navoi branch of the Republican Scientific Center for Emergency Medical Care, Navoi, Republic of Uzbekistan.

\*Correspondence to: Mardonov Jamshid Normurotovich (E-mail: doctor\_jamshid@inbox.ru)

(Submitted: 26 August 2024 – Revised version received: 10 September 2024 – Accepted: 04 October 2024 – Published online: 26 December 2024)

## Abstract

**Objective:** To evaluate the efficacy of localized hypothermia as a tissue-protection strategy in mitigating ischemic and inflammatory damage during colon strangulation. Specifically, this study aimed to assess the impact of hypothermia on colon wall thickness, inflammatory cell infiltration, and pro-inflammatory cytokine levels in a controlled experimental model using white rats. By comparing outcomes between hypothermia-treated and untreated groups, the research sought to provide insights into the potential of hypothermia as an adjunctive therapy to enhance surgical outcomes and reduce complications associated with strangulated hernias.

**Methods:** This experimental study involved 40 white rats with induced colon strangulation, divided into control ( $n = 20$ ) and hypothermia ( $n = 20$ ) groups. Local hypothermia was applied to the abdominal region at 13°C for 3–6 hours. The study evaluated colon wall thickness, inflammatory infiltrate area, macrophage counts, and levels of pro-inflammatory cytokines (IL-1 $\beta$ , IL-6, TNF- $\alpha$ ) using histological, morphometric, and biochemical methods. Statistical significance was determined using Student's t-test ( $P < 0.05$ ).

**Results:** Hypothermia significantly reduced colon wall thickness ( $0.5 \pm 0.2$  mm vs.  $1.2 \pm 0.3$  mm in the control,  $P < 0.01$ ), inflammatory infiltrate area ( $5,000 \pm 1,500$   $\mu\text{m}^2$  vs.  $12,000 \pm 3,000$   $\mu\text{m}^2$ ,  $P < 0.05$ ), and macrophage counts ( $50 \pm 10$  cells vs.  $100 \pm 20$  cells,  $P < 0.05$ ). Pro-inflammatory cytokine levels (IL-1 $\beta$ , IL-6, TNF- $\alpha$ ) decreased by 45.8%, 47.4%, and 56.3%, respectively, in the hypothermia group compared to the control group ( $P < 0.01$  for all). These findings confirm hypothermia's anti-inflammatory and tissue-protective properties.

**Conclusions:** Hypothermia demonstrates significant potential in minimizing ischemic and inflammatory damage in cases of colon strangulation, reducing tissue edema and inflammatory cell infiltration. This approach may improve surgical outcomes and warrants further exploration for integration into clinical practice.

**Keywords:** Hypothermia, large intestine, incarceration, inflammation, cytokines, surgery

## Introduction

Intestinal strangulation, including that of the large intestine, in hernial disease is one of the most complex and pressing problems in modern surgery. The pathological changes during strangulation are based on ischemia, reperfusion syndrome, hypoxia, and subsequent inflammatory reactions, which lead to disruption of microcirculation, damage to the mucous and submucous layers of the intestinal wall, and ultimately, to necrotic changes in the tissues of the large intestine. These pathological processes contribute to the development of severe complications, including peritonitis, sepsis, and multiple organ failure, which significantly increase mortality rates, reaching 35–50% in the absence of timely treatment.<sup>1,2</sup>

The large intestine, being highly sensitive to ischemia due to the peculiarities of its blood supply and cellular energy metabolism, undergoes significant structural changes when strangulated. The disruption of blood circulation in its wall is accompanied by the activation of endothelial cells, increased capillary permeability, enhanced exudation, and leukocyte migration. Against the background of hypoxia, an imbalance occurs between the processes of apoptosis and necrosis of the mucosal cells, which exacerbates the inflammatory response and contributes to the progression of damage.<sup>3</sup>

Modern methods of tissue protection, such as pharmacological drugs (antioxidants, anti-inflammatory agents) and surgical interventions, do not always ensure full prevention of ischemic and inflammatory damage to the colon wall. This is due to the limitation of their action at the systemic level, insufficient specificity to local pathological changes, and the inability of tissues to quickly adapt to acute changes in microcirculation. Therefore, the search for alternative and additional approaches to tissue protection in conditions of intestinal strangulation remains extremely important.

Hypothermia, as a method of active tissue protection, demonstrates significant potential in preventing ischemic and inflammatory damage. Its mechanism of action includes reducing the metabolic activity of cells, decreasing the production of pro-inflammatory mediators such as interleukin-1 $\beta$  (IL-1 $\beta$ ), interleukin-6 (IL-6), and tumor necrosis factor- $\alpha$  (TNF- $\alpha$ ), as well as stabilizing cell membranes and improving microcirculation.<sup>4,5</sup> In addition, hypothermia contributes to a decrease in capillary permeability and suppresses leukocyte migration to the damaged area, which reduces tissue edema and exudation.<sup>6</sup>

Studies dedicated to the application of hypothermia have shown its effectiveness in various areas of surgery, including organ transplantation, cardiac surgery, and the treatment of

acute abdominal conditions. However, the clinical potential of hypothermia in large intestine strangulation has not been sufficiently studied. Data on its influence on the morphological changes in the wall of the large intestine, as well as on the level of pro-inflammatory cytokines and the functional state of tissues under ischemic conditions, remain limited.

**The aim of this study is** to investigate the influence of hypothermia on morphological changes in the large intestine wall in cases of strangulated hernias. Particular attention is paid to analyzing the intestinal wall thickness, the degree of inflammatory infiltrate, the number of macrophages, as well as the level of key pro-inflammatory mediators. The obtained data will allow not only to assess the effectiveness of hypothermia as a method of tissue protection but also to determine its place in the treatment algorithm for strangulated hernias of the colon. Improving the understanding of hypothermia's mechanisms of action and its impact on damaged tissues will also contribute to the development of more effective approaches to surgical treatment of such patients.

## Materials and Methods

**Research design.** The experimental study was conducted using a model of colon strangulation in laboratory animals. The study was carried out from 2023 to 2024 at the Department of Experimental Surgery of the State Institution "Republican Specialized Scientific and Practical Medical Center of Surgery named after Academician V. Vakhidov".

**Research subjects.** The experiment involved 40 white, outbred rats of both sexes, weighing 210–249 g. The animals were kept in vivarium conditions at a stable temperature of 22–24°C, with free access to food and water. All procedures were performed under general anesthesia using a ketamine solution (100 mg/kg) and diazepam (5 mg/kg), in accordance with ethical principles (Strasbourg Declaration, 1996).<sup>3</sup>

Animal groups:

- Control group ( $n = 20$ ): modeling of colon strangulation without using additional protective methods.
- Hypothermia group ( $n = 20$ ): modeling of colon strangulation with local cooling of the abdominal region to 13°C for 3–6 hours.

**Application of hypothermia.** To carry out local cooling, specialized equipment was used, which ensured accurate maintenance of the exposure temperature. Thermal sensors, placed directly on the surface of the colon wall, allowed for the control of cooling levels and prevented overheating or overcooling of tissues beyond permissible values. The exposure was continued until a uniform temperature was achieved in the strangulation zone.

## Evaluation Methods

- **Histological examination.** Colon tissue biopsies were fixed in a 10% formalin solution, after which histological preparations were made and stained with hematoxylineosin. The analysis was performed under a light microscope to assess structural changes in the intestinal wall.
- **Morphometry.** A quantitative analysis was conducted on the thickness of the colon wall (mm), the area of inflammatory infiltrate ( $\mu\text{m}^2$ ), and the number of macrophages per

unit area. Digital microscopes with morphometric capabilities were used for measurements.

- **Biochemical analysis.** Colon tissue samples were used to determine the levels of pro-inflammatory cytokines (IL-1 $\beta$ , IL-6, TNF- $\alpha$ ). Cytokine levels were measured using the enzyme-linked immunosorbent assay (ELISA) method with commercial analysis kits.

**Statistical analysis.** All obtained data were processed using statistical analysis software (Statistica 7 program). The results are presented as mean (M) and standard deviation (SD). Student's t-test for independent samples was used to assess the statistical significance of differences between groups. Differences were considered statistically significant at a significance level of  $P < 0.05$ .

## Results

**Thickness of the colon wall.** In the control group, the thickness of the colon wall was  $1.2 \pm 0.3$  mm, reflecting pronounced inflammatory edema resulting from impaired microcirculation and increased capillary permeability. In the hypothermia group, this parameter was  $0.5 \pm 0.2$  mm ( $P < 0.01$ ), indicating a significant reduction in edema and inflammatory processes under the influence of local cooling. Hypothermia demonstrated the ability to decrease the severity of the inflammatory response by stabilizing the vascular wall and suppressing exudation<sup>4,5</sup> (Fig. 1).

**Area of inflammatory infiltrate.** In the control group, the area of inflammatory infiltrate in the colon was  $12,000 \pm 3,000$   $\mu\text{m}^2$ , indicating active involvement of inflammatory cells such as neutrophils, macrophages, and lymphocytes in the damaged tissue. In the hypothermia group, the area of inflammatory infiltrate decreased to  $5,000 \pm 1,500$   $\mu\text{m}^2$  ( $P < 0.05$ ). This reduction is associated with suppression of pro-inflammatory processes, decreased recruitment of inflammatory cells, and reduced secretion of pro-inflammatory mediators. The results confirm the anti-inflammatory properties of hypothermia, which are expressed in decreased neutrophil migration and reduced tissue damage<sup>6,7-10</sup> (Fig. 1).

**Number of macrophages.** Macrophages play a key role in inflammatory processes, participating in phagocytosis, secretion of pro-inflammatory cytokines, and activation of other immune cells. In the control group, the average number of macrophages in the colon tissue was  $100 \pm 20$  cells per unit area. In the hypothermia group, this indicator decreased to  $50 \pm 10$  cells ( $P < 0.05$ ). The decrease in the number of macrophages under the influence of hypothermia is associated with suppression of monocyte chemotaxis, reduced production of pro-inflammatory mediators such as IL-1 $\beta$  and TNF- $\alpha$ , and overall attenuation of the inflammatory response<sup>4</sup> (Fig. 1).

**Level of pro-inflammatory cytokines.** A significantly elevated level of pro-inflammatory cytokines was observed in the colon tissues of the control group:

- IL-1 $\beta$ :  $120 \pm 15$  pg/ml;
- IL-6:  $95 \pm 12$  pg/ml;
- TNF- $\alpha$ :  $80 \pm 10$  pg/ml.

In the hypothermia group, the level of cytokines decreased:

- IL-1 $\beta$ :  $65 \pm 10$  pg/ml ( $P < 0.01$ );
- IL-6:  $50 \pm 8$  pg/ml ( $P < 0.01$ );
- TNF- $\alpha$ :  $35 \pm 7$  pg/ml ( $P < 0.01$ ).

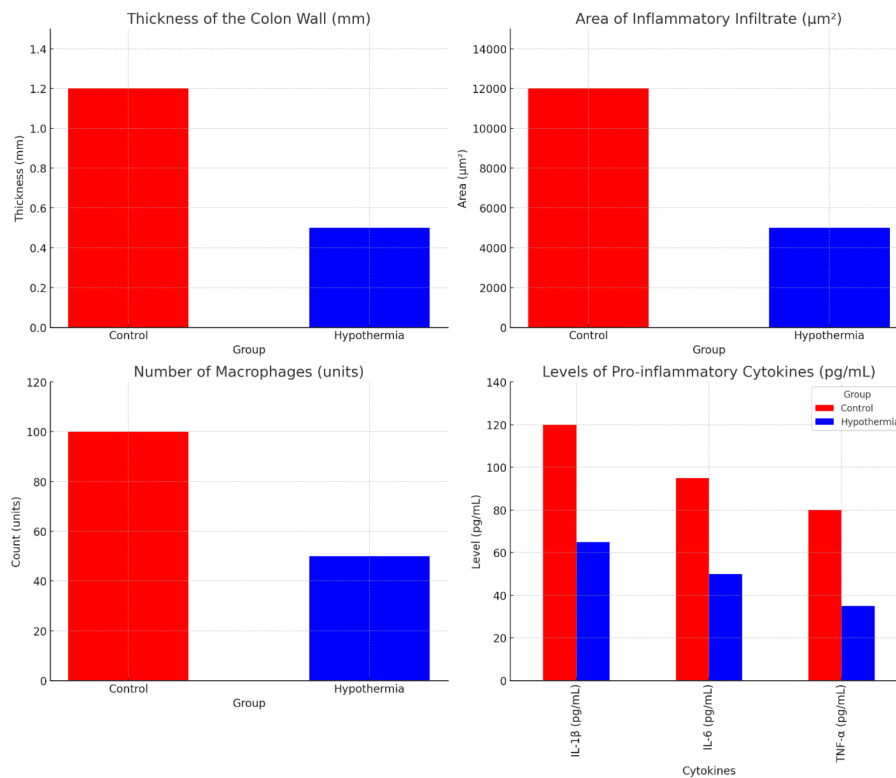


Fig. 1 Comparative-diagram representation of the obtained data.

The reduction in pro-inflammatory mediator levels under the influence of hypothermia indicates suppression of the inflammatory response and a decrease in the activity of inflammatory cells<sup>7-10</sup> (Fig. 1).

## Discussion

The results of this study confirm the pronounced protective properties of hypothermia in colon strangulation. A significant decrease in the thickness of the large intestine wall, a reduction in the area of inflammatory infiltrate and the number of macrophages, as well as suppression of pro-inflammatory cytokines (IL-1β, IL-6, TNF-α) indicate the ability of hypothermia to effectively prevent ischemic and inflammatory tissue damage.

The main mechanism of action of hypothermia is a decrease in the metabolic activity of cells and a reduction in the production of pro-inflammatory mediators. Under hypothermic conditions, cell membranes stabilize, vessel permeability decreases, and the migration of inflammatory cells into the tissue is suppressed.<sup>10</sup> This leads to a decrease in tissue edema and infiltration, which is confirmed by a 58.3% reduction in the area of inflammatory infiltrate in the hypothermia group compared to the control group.

These data are consistent with the research of Hartmann et al. (2019), which demonstrated that hypothermia reduces structural changes in the intestinal wall, preventing cell apoptosis and stabilizing tissue morphology. Additionally, the work of Krarup et al. (2013) showed that local cooling suppresses free radical formation and improves microcirculation, which is crucial for protecting tissues from reperfusion injury. In addition, the work of Krarup et al. (2013) showed that local cooling suppresses free radical formation and improves

microcirculation, which is important for protecting tissues from reperfusion damage.

Another important aspect of hypothermia's action is its ability to reduce the levels of key pro-inflammatory cytokines, which contributes to the attenuation of the inflammatory response. Under hypothermic conditions, IL-1β levels decreased by 45.8%, IL-6 by 47.4%, and TNF-α by 56.3% compared to the control group, highlighting the significant anti-inflammatory effect of this method.

The clinical significance of hypothermia extends beyond the treatment of strangulated colon hernias. It is actively used in transplantology to prevent ischemia in transplanted organs, in cardiac surgery to protect the myocardium during cardiac arrest, and in the treatment of abdominal complications. These data underscore the versatility and broad prospects of using hypothermia in surgical practice.<sup>5,6</sup>

However, there remain questions that require further study. It is necessary to determine the optimal parameters for applying hypothermia, including the duration of exposure and temperature range. Furthermore, standards need to be developed for integrating hypothermia into existing treatment protocols for strangulated hernias and other critical conditions.

## Conclusion

Hypothermia demonstrates high effectiveness in protecting the tissues of the large intestine in strangulated hernias. The obtained results confirm its ability to:

- Reduce the thickness of the colon wall.
- Decrease the area of inflammatory infiltrate.
- Reduce the number of macrophages.
- Suppress levels of pro-inflammatory cytokines (IL-1β, IL-6, TNF-α).

These effects contribute to minimizing ischemic and inflammatory damage, which improves the prognosis of surgical treatment for patients with strangulated hernias. Developing and implementing standards for the use of hypothermia will optimize its application in clinical practice, improve treatment quality, and reduce the risk of complications.

Further research aimed at studying the mechanisms of hypothermia action and optimizing its parameters will facilitate the integration of this method into a wide range of surgical practices.

## Conflict of Interest

None. ■

## References

- Hayanga A. J., Bass-Wilkins K., Bulkley G. B. Current management of small-bowel obstruction // *Adv Surg.* — 2005. — T. 39. — C. 1–33.
- Cappell M. S., Batke M. Mechanical obstruction of the small bowel and colon // *Med. Clin. North. Am.* — 2008. — T. 92. — C. 575–97.
- Hartmann L., Zhao X., Macheroux T., et al. Time-Dependent Alterations of Gut Wall Integrity in Small Bowel Obstruction in Mice // *J Surg Res.* — 2019. — T. 233. — C. 249–255.
- Krärup P. M., Rehn M., Sand-Dejmek J., et al. Rapid morphological changes and loss of collagen following experimental acute colonic obstruction // *Int J Colorectal Dis.* — 2013. — T. 28. — № 3. — C. 341–7.
- Dayton M. T., Dempsey D. T., Larson G. M., Posner A. R. New paradigms in the treatment of small bowel obstruction // *Curr Probl Surg.* — 2012. — T. 49. — C. 642–717.
- Li Z., Zhang L., Liu X., Yuan F., Song B. Diagnostic utility of CT for small bowel obstruction: Systematic review and meta-analysis // *PLoS One.* — 2019. — T. 14. — № 12. — e0226740.
- Shukhratovich, S.D., Abrarovich, S.R., Yusupovich, R.R., Nunyazovich, K.B., Radjabovich, Y.F., Normurotovich, M.J., & Khujayazovna, K.K. Physico-Chemical Properties of the New Domestic Mesh Implant "Niprocel". *Central Asian Journal of Medical and Natural Science* 2024, 5(2), 51–59.
- Radjabovich, Y. F., Shukhratovich, S. D., & Nunyazovich, K. B. (2023). Modern Aspects of Prevention of Hernias of the Linea Alba of the Abdomen After Laparotomy. *Research Journal of Trauma and Disability Studies*, 2(4), 139–142. <https://journals.academiczone.net/index.php/rjtds/article/view/702>
- Baymakov S. R. et al. Assessment of the risk of scar stricture of the anal canal depending on the choice of treatment method for hemorrhoidectomy // *Multidisciplinary Journal of Science and Technology.* – 2024. – T. 4. – № 5. – C. 547–552.
- Yakubov F.R., Sadykov R.A., Mardonov J.N., Erniyazov E.A., Sapaev D.S. Evaluation of Hemostatic Efficacy of Hemoben Gel in Ruptures of the Gastric Mucosa in an Experiment. *Bull. Env. Pharmacol. Life Sci.*, Vol 12 [8] July 2023: 56–66.

This work is licensed under a Creative Commons Attribution-NonCommercial 3.0 Unported License which allows users to read, copy, distribute and make derivative works for non-commercial purposes from the material, as long as the author of the original work is cited properly.